



MINISTRY OF EDUCATION AND SCIENCE OF THE RUSSIAN FEDERATION
Federal state autonomous educational institution
of higher education
«Far Eastern Federal University»
(FEFU)

SCHOOL OF BIOMEDICINE

«AGREED»

Head of education program
«General medicine»



(signature) Khotimchenko Yu.S.
(Full name)
«09» of July 2019

«APPROVED»

Director of the Department of Clinical
Medicine





(signature) Geltser B.I.
(Full name)
«09» of July 2019

WORKING PROGRAM OF ACADEMIC DISCIPLINE (WPAD)

«Roentgenology, Radiodiagnostics»

Education program

Specialty 31.05.01 «General medicine»

Form of study: full time

year 3, semester 6
lectures 18 hours
practical classes 36 hours
laboratory works not provided
total amount of in-classroom works 54 hours
independent self-work 54 hours
control works ()
credit year 3, semester 6
exam not provided

The working program is drawn up in accordance with the requirements of the Federal state educational standard of higher education (level of training), approved by the order of the Ministry of education and science of the Russian Federation from 09.02.2016 № 95.

The working program of the discipline was discussed at the meeting of the Department of fundamental and clinical medicine. Protocol No. 8, 09 of July 2019

Authors: c.m.sc., docent Jevaga A.B., c.m.sc., docent Kuzmenko E.A.

RESUME

Discipline " Roentgenology, Radiodiagnostics" is included in the variable part of the curriculum discipline of choice, implemented in the 3rd year in the 6th semester. The total complexity of the discipline is 108 hours, 3 credits.

In the development of the working program of the discipline used the Federal state educational standard of higher education in the specialty 31.05.01 "Medical care" (level of training specialty).

The course program is based on the basic medical knowledge obtained by specialists:

- the willingness to solve common tasks of professional activity with the use of information and bibliographic resources, biomedical terminology, information and communication technologies, taking into account the main requirements for information security (GPC – 1)

the readiness to use basic physical and chemical, mathematical and other natural science concepts and methods in solving professional problems (GPC – 7)

The purpose of the development of the discipline is the formation of students 'professional knowledge on radiology, radiation diagnosis, the formation of students' fundamentals of clinical thinking, professional skills, informed, integrated use of imaging techniques necessary for further training and professional activities in medical specialties; mastering the basics of examination, diagnosis of patients with various nosological forms necessary for subsequent independent medical activity.

Objectives.

1. Training in the discipline of radiology, radiology, revealing in its sections of radiation detection methods of pathology of all organs and systems in patients in clinical practice.

2. Deepening and consolidation of students ' knowledge of the physical foundations of radiation diagnosis, technologies for obtaining x-ray and ultrasound images, as well as the mechanisms of biological action of various types of radiation on the tissue.

3. To systematize the existing knowledge and formation of students ' ideas about modern methods of radiation diagnosis. To develop the ability of rational choice of the method of radiological examination, examination of the patient by methods of x-ray, echography, possession of concepts and interpretation of the obtained data of x-ray and ultrasound in the diagnosis of common diseases and conditions.

4. Providing theoretical knowledge and practical skills, the breadth of scientific approach to solving problems of radiology, radiology.

5. Formation of students ' skills in the study of scientific literature and official statistical reviews on the sections of the discipline, the preparation of reviews of modern scientific problems in the field of radiation diagnosis.

6. The combination of specific knowledge in the discipline of radiology, radiology with methodological and interdisciplinary aspects, allowing to form specialists with a broad Outlook, able to perceive their professional activities as a means of solving a complex of medical, economic, moral, ethical and social problems.

To solve these problems, a course of thematic lectures, clinical analysis of patients, the development of modern diagnostic methods and methods of treatment is planned.

As a result of the study of this discipline, students form the following competencies:

Competence and its code	Stages of competence formation	
the capacity for the assessment of morphological and physiological states and pathological processes in the human body for solving professional tasks (GPC – 9)	Knows	Methods of implementation of set of measures aimed at the preservation and promotion of health, methods of assessment of natural and social environmental factors in the development of human diseases, forms and methods of sanitary and educational work;
	Able to	Assess the causes and conditions of the induction and development of diseases in humans; to assess the natural and social factors of the environment in the development of human diseases; to search for solutions to various problems in unusual situations, to carry out sanitary and educational work with the population and patients;
	Masters	Methods of assessment of natural and social environmental factors in the development of human diseases; the basics of preventive measures to prevent diseases; the principles of sanitary and educational work on hygienic issues,

Competence and its code	Stages of competence formation	
the readiness to collect and to analyze patient complaints, data of its history, the results of laboratory, instrumental, postmortem and other examinations to recognize the incidence or the absence of diseases (PC – 5)	Knows	General and special research methods in the main sections of therapy; basics of ultrasound and methods of radiation diagnostics in various sections of medicine.
	Able to	obtain information about the development and course of the disease; to identify general and specific radiological and US signs of the disease; to assess the severity of the patient's condition; to determine, interpret the data.
	Masters	Skills that allow to establish a diagnosis based on the results of X-ray and US methods in the most common therapeutic diseases;
the ability of determining the patient's basic pathological conditions , symptoms, syndromes, diseases in accordance with the International Statistical Classification of Diseases and problems related to health , the 10th review. (PC – 6)	Knows	Physical and technical basis of radiation diagnosis. Technologies for obtaining images of biological tissues and organs, methods of radiation examination, rules of patient preparation, basic accesses, scanning modes. Possibilities of methods of radiation diagnosis in modern clinical practice.
	Able to	Distinguish between the normal picture and anatomical and physiological parameters of X-ray and sonography of organs and images typical of common diseases. Interpret X-ray and sonograms in typical pathological processes and evaluate the conclusion of a specialist of radiation diagnosis
	Masters	Skills of diagnosis according to X-ray and US methods of research

I. THE STRUCTURE AND CONTENT OF THE THEORETICAL PART OF THE COURSE (18 hours)

Module 1. Topical issues of radiology (9 hours)

Theme 1. General issues of radiation diagnostics (2 hours).

The history of radiation diagnostics and further development of the discipline its connection with other medical and biological problems, the relationship of radiation diagnosis with other instrumental methods of research.

Theme 2. Radiation diagnostics of diseases of the chest cavity (2 hours).

Anomalies and malformations, acute and chronic lung diseases, suppurative diseases of the bronchi and lungs, degenerative diseases of the lungs (emphysema, pneumosclerosis, "disappearing lung", etc.).

Theme 3. Radiation diagnostics of diseases of the digestive system (2 hours).

Overview study of the digestive system, abdominal cavity.

Oral contrast. Excretory (oral and intravenous) cholecystocholangiography, fistulography. Multidirectional and polypositional study. Study of the use of functional tests and pharmacological agents. Relaxation techniques (pharyngography, duodenography, ileocecectomy).

Theme 4. Radiation diagnostics of diseases of the cardiovascular system (2 hours).

The diagnosis of mitral, aortic, mitral-aortic, mitral-tricuspid vices, mitral-aortic-tricuspid vices, and birth defects. Myocardial lesions in myocarditis, myocardiodystrophy, coronary artery disease, hypertension.

Theme 5. Radiation diagnostics of diseases and injuries of the genitourinary system (1 hour).

The most common anomalies, inflammatory diseases of the kidneys and urinary tract, nephroptosis, hydronephrosis, urolithiasis. Malignant and benign tumors. Vascular lesions of the kidneys.

Module 2. Topical issues of ultrasound diagnostics (USD) (9 h)

Theme 1. General issues of ultrasound diagnostics (1 hour).

Physical and technical basis of ultrasonic research method, ultrasonic diagnostic equipment. Physical properties of ultrasound. History and development of ultrasound diagnostics. Physical principles of ultrasonic research methods and mechanisms of biological action of ultrasound. Application of ultrasonic methods in medicine.

Theme2. Ultrasound diagnostics in gastroenterology (2 hours).

Ultrasound examination of the hepato-pancreato-biliary system and spleen. Ultrasound anatomy of the liver, gallbladder, pancreas, spleen is normal. Echographic picture of the liver, gallbladder, pancreas, spleen. Ultrasound technology. Standard medical report.

Theme 3. Ultrasound diagnosis of urinary system, adrenal glands (2 hours).

Ultrasound examination of kidneys, adrenal glands, ureters, bladder. Ultrasound anatomy and echographic picture of the kidneys, adrenal glands, ureters, bladder are normal. Ultrasound technology. Standard medical report.

Theme 4. Ultrasound diagnostics in cardiology (2 hours)

Echocardiography. Basic position. Scan mode. Left ventricular systolic and diastolic function. Standards in echocardiography. Standard medical report.

Theme 5. Ultrasound diagnostics in angiology (2 hours).

Fundamentals of ultrasound examination of the vascular system. Dopplerography. Color duplex scanning of the main arteries of the head, transcranial duplex scanning. CDS of the abdominal aorta and its visceral branches, peripheral arteries and veins. Standard medical report.

I. THE STRUCTURE AND CONTENT OF THE PRACTICAL PART OF THE COURSE (54 hours)

Section 1. Radiology (27 hours)

Lesson 1. The subject of radiology and its place in modern clinical medicine (1 hour).

Radiology as a clinical discipline. The main methods of X-ray examination. Fluoroscopy. Radiography. The value of the projection in radiology. Standard projections (straight, side, oblique). Non-standard projections.

Lesson 2. Construction of X-ray diagnosis (1 hour).

Stages of X-ray diagnostics. Schemes and methods of analysis. Radiological symptoms and syndromes. Synthesis of clinical and radiological data. Setting group and novological diagnosis. Topic diagnostics (localization, process distribution.) Qualitative diagnostics (form, phase of the process). Differential diagnostics. Diagnostics of complications (decay, pathological fracture, etc.). Formulation of X-ray diagnosis. Preparation of the protocol for X-ray examination.

Lesson 3. Chest X-ray anatomy (1 hour)

Lobar and zonal structure of the lungs. Segmental structure. The structure of the tracheobronchial tree. Anatomy of vessels of the small circle of blood circulation and bronchial arteries on angiograms. Pulmonary pattern and its anatomical substrate.

Lesson 4. The total X-ray semiotics of the chest cavity (3 hours)

The scheme of analysis of pathological shadows in the lungs. Localization. Number of shadows. Form. Dimensions. The intensity of the shadow, densitometry. The shade structure. The contours of the shadows. The state of the surrounding lung tissue.

Dislocation and compression of the trachea. Foreign bodies in trachea. Expiratory collapse of trachea. Tracheal tumors are benign and malignant. Differential diagnostics and the importance of special research methods.

Anomalies and malformations of lungs and bronchi. Defects associated with underdevelopment of bronchial tree. Agenesis, aplasia of the lung lobe. Simple hypoplasia of the lung, lobes. Cystic hypoplasia. True bronchopulmonary cyst, cysts. Malformations of the tracheal and bronchial walls.

Lesson 5. Acute inflammatory diseases of bronchi and lungs (3 hours)

Acute bronchitis and bronchiolitis. Bacterial pneumonia. Viral pneumonia. Mycoplasma pneumonia. Rickettsiosis pneumonia. Pneumocystic pneumonia. Fungal pneumonia. Parasitic pneumonia. Allergic pneumonia. Changes in the lungs with AIDS.

Lesson 6. Chronic inflammatory and suppurative diseases of the bronchi and lungs. Pulmonary tuberculosis (2 hours)

Chronic bronchitis. Bronchiectasis primary and secondary. Bronchoectatic disease.

Pulmonary tuberculosis. Primary tuberculosis complex. Tuberculosis of intrathoracic lymph nodes. Disseminated tuberculosis of the lungs. Focal pulmonary tuberculosis. Infiltrative pulmonary tuberculosis. Tuberculosis. Cavernous tuberculosis. Fibrous-cavernous tuberculosis.

Lesson 7. Pleural diseases (2 hours).

Pleural effusions. Inflammatory effusions (exudative pleurisy) in purulent-inflammatory processes in the body. Allergies and autoimmune effusion. Effusions in diffuse connective tissue diseases. Post-traumatic effusions. Stagnant fluids.

Lesson 8. Methods of investigation of the digestive system and abdominal cavity. X-ray assessment of the stomach (3 hours)

Methods of non-contrast research. The technique of non-contrast study of the pharynx and esophagus. Non-contrast study of the abdominal cavity. Methods of contrast examination of the pharynx and esophagus. Studies with water-soluble contrast. Study with barium suspension of different concentrations. Double contrast. Functional x-ray diagnostics.

X-ray assessment of the stomach. X-ray nomenclature of the stomach parts. The main constitutional forms of the stomach. Mucosal relief: macro-relief and microrelief. X-ray evaluation of tonic, peristaltic, evacuation, secretory function of the stomach. Radiographic evaluation of the functions of the sphincters of the stomach.

Lesson 9. X-ray assessment of diseases of the small intestine and colon (2 hours)

X-ray anatomical characteristics of the intestine. Atresia and stenosis. Congenital giant duodenum (megabalanus, megabonus). Doubling. Congenital diverticula. Meckel's diverticulum. Microcolon. Megacolon. Hirschsprung's disease.

Lesson 10. X-ray evaluation of diseases of the biliary tract and pancreas (2 hours)

X-ray anatomical characteristics of the biliary tract and pancreas . Atresia and stenosis. X-ray evaluation of the secretory function of the liver, pancreas. Inflammatory disease.

Lesson 11. Methods of study of the heart and blood vessels. Heart defects (3 hours)

No contrast techniques. Fluoroscopy. Radiography. Fluorography. Electroretinography. Radiometry. Mitral defects. Mitral stenosis. Mitral insufficiency. Combination of stenosis and insufficiency. Differential X-ray diagnostics of mitral stenosis and insufficiency. Coarctation. X-ray surgical treatment. Isolated stenosis of the pulmonary artery. X-ray surgical treatment. Aortic stenosis. Defects with increase in minute volume in a small circle of blood circulation.

Lesson 12. X-ray anatomy of urinary system. Anomalies and malformations of kidneys (2 hours)

X-ray anatomy of the retroperitoneal space. X-ray of the kidneys, adrenal glands, urinary tract. Anomalies in number of kidneys. Anomalies of location. Structure anomalies. Anomalies of the ureters. Other anomalies and malformations.

Lesson 13. X-ray diagnostics of inflammatory diseases of the kidneys and upper urinary tract (2 hours)

Acute pyelonephritis. Carbuncle of the kidney. The paranephritis. Chronic pyelonephritis. Tuberculosis of the urinary system. X-ray diagnostics of urolithiasis. X-ray diagnostics of hydronephrosis and dilatation of the upper urinary tract. X-ray diagnostics of kidney cysts. Solitary, multiple cysts, polycystic. Tumors of the kidney.

Section 2. Ultrasound diagnosis (27 hours)

Lesson 1. General issues of ultrasound diagnostics (2 hours).

Organization of ultrasound diagnostics service. Normative documents on ultrasonic diagnostics. Physical and technical basis of ultrasonic research method, ultrasonic diagnostic equipment, sensors. New directions in ultrasound diagnostics. Minor surgical interventions under control of ultrasound. Puncture biopsy. Intraoperative echography. Sonoelastography. Ultrasound for emergency conditions.

Lesson 2. Basics of ultrasound diagnosis in the pathology of the abdominal cavity (3 hours).

Ultrasound diagnostics of diseases of the liver, biliary system, pancreas, spleen: indications for ultrasound examination, the main accesses and scanning planes.

Injuries of the abdominal cavity, ultrasound picture. Interpretation of echograms in the pathology of the abdominal cavity and evaluation of ultrasound data in combination with the clinical picture of diseases.

Lesson 3. Fundamentals of ultrasound diagnostics in the pathology of the urinary system (2 hours).

Ultrasonic diagnostics of urinary system. Ultrasonic diagnostics of diseases of kidneys, adrenal glands, bladder: indications for ultrasound examination, the main accesses and the scan plane. Kidney and urinary tract injuries. Interpretation of echograms in the pathology of the urinary system and evaluation of ultrasound data in combination with the clinical picture of diseases.

Lesson 4. Ultrasound examination in diseases of the endocrine system (2 hours).

Technology of ultrasound examination of the thyroid gland. Indications for ultrasound examination of the thyroid gland. Ultrasound anatomy of the thyroid gland, scanning plane. Anomalies of development, shape, location, thyroid gland. Ultrasound diagnostics of diffuse thyroid lesions. Diffuse goiter. Thyroiditis. Ultrasound diagnostics of focal thyroid lesions. Developing and promising methods of ultrasound examination of the thyroid gland. Standard medical report on the results of ultrasound examination of the thyroid gland. Interpretation of echograms in thyroid pathology, evaluation of ultrasound data in combination with the clinical picture of diseases.

Lesson 5. Ultrasound examination of the heart. Echocardiography in hypertensive disease, coronary heart disease, myocardial infarction, complications of myocardial infarction (left ventricular aneurysm, thrombosis, wall rupture) (4 hours).

Technology of ultrasound examination of the heart. Scan mode. Left ventricular hypertrophy. Systolic and diastolic function. Coronary heart disease. Heart attack. Complications of myocardial infarction. Left ventricular aneurysm. Interpretation of echograms in heart disease and evaluation of ultrasound data in combination with the clinical picture of diseases. Stress echocardiography, indications. The main indications for esophageal Echocardiography.

Lesson 6. Ultrasound examination of the heart. Echocardiography in the diagnosis of cardiomyopathy, connective tissue dysplasia (STD), small abnormalities of the heart (SAH) (3h).

Types of cardiomyopathy. Dilated, hypertrophic, retroactive cardiomyopathy and its causes. Connective tissue dysplasia syndrome. Prolapse. Interpretation of echograms and evaluation of ultrasound data in combination with the clinical picture of diseases.

Lesson 7. Ultrasound examination of the heart. Echocardiography in the diagnostics of myocarditis, endocarditis, pericarditis (2 hours).

Myocarditis. Bacterial endocarditis, etiology. Constrictive pericarditis. Signs of cardiac tamponade. Interpretation of echograms in heart disease and evaluation of ultrasound data in combination with the clinical picture of diseases.

Lesson 8. Echocardiography in the diagnosis of congenital and acquired heart defects (3 hours).

Acquired heart defects. Stenosis, valve failure. Reasons. Congenital heart disease. Double AC. Coarctation. Atrial and ventricular septal defect. Open arterial (Batalov) duct. Fallot's disease. Ebstein's anomaly. Eisenmenger syndrome. Myxoma.

Lesson 9. Color duplex scanning in detection of arterial pathology (4 hours).

Anatomy and ultrasound anatomy of the brachycephalic arteries, the main arteries of the limbs. Technology of ultrasound examination of the arterial system. Indications for ultrasound examination of arteries. Scan mode. Dopplerography. Anomalies of the main arteries. Atherosclerotic lesion. Vasculitis. Nonspecific aortoarteritis. Aneurysm. Pathological deformities. Endarteritis. raynaud. Interpretation of echograms in the pathology of arteries and measurement of these ultrasonic examinations together with the clinical picture of the disease.

Lesson 10. Color duplex scanning in detection of peripheral vein pathology (2 hours).

Anatomy and ultrasound anatomy of the main veins of the neck and extremities. Technology of ultrasound examination of the arterial system. Scan mode. Indications for ultrasound examination of veins. Varicose veins. Thrombosis and thrombophlebitis. Post-thrombotic disease. Angiodysplasia. Interpretation of echograms in the pathology of veins and assessment of data of ultrasonic studies in conjunction with the clinical picture of the disease.

Lesson 11. Credit. The overall test control. Interview

TRAINING AND METHODOLOGICAL SUPPORT OF INDEPENDENT WORK OF STUDENTS

The main content of the topics, evaluation tools are presented in the WPAD: terms and concepts necessary for mastering the discipline.

During the mastering the course “Radiology, radiation diagnostics”, the student will have to do a large amount of independent self-work, including preparation for seminars and writing an essay.

Practical classes help students to deeper learn the material, to acquire the skills of creative work on documents and primary sources.

Plans for practical classes, their topics, recommended literature, the purpose and objectives of its study are communicated by the teacher at the introductory classes or in the curriculum for the discipline.

Before starting to study the topic, it is necessary to familiarize yourself with the basic questions of the practical training plan and the list of recommended literature.

Starting the preparation for the practical lesson, first of all it is necessary to refer to the lecture notes, sections of textbooks and teaching aids in order to get a general idea of the place and significance of the topic in the course being studied. Then work with additional literature, make notes on the recommended sources.

In the process of studying the recommended material it is necessary to understand the construction of the topic being studied, highlight the main points, trace their logic and thereby get into the essence of the problem being studied.

It is necessary to keep records of the material being studied in the form of an outline, which, along with the visual, includes the motor memory and allows you to accumulate an individual fund of auxiliary materials for a quick repetition of what you read, to mobilize accumulated knowledge. The main forms of writing: a plan (simple and detailed), extracts, theses.

In the preparation process, it is important to compare the sources, think over the material being studied and build an algorithm of actions, carefully consider your oral presentation.

At a practical lesson, each participant should be ready to speak on all the questions posed in the plan, to be as active as possible in their consideration. The speech should be convincing and reasoned, and simple reading of an essay is not allowed. It is important to show own attitude to what is being said, express your personal opinion, understanding, substantiate it and draw the right conclusions from what has been said. Student can refer to notes of references and lectures, directly to primary sources, use the knowledge of monographs and publications, facts and observations of modern life, etc.

A student who did not have time to speak at a practical lesson can present a prepared summary to the teacher for verification and, if necessary, answer the teacher's questions on the practical lesson to get a credit score on this topic.

The teaching and methodological support of students' independent work in the discipline "Radiology, radiation diagnostics" is presented in Appendix 1 and includes:

- characteristics of tasks for independent self-work of students and methodological recommendations for their implementation;
- requirements for the reports and presentation of the results of independent self-work;
- criteria for assessment of execution of the independent self-work.

MONITORING THE ACHIEVEMENT OF THE OBJECTIVES OF THE COURSE

No.	Controlled sections / topics of disciplines	Codes and stages of the formation of competencies	Assessment tools - name		
			Current control	Intermediate certification	
	Module 1. Topical issues of radiology	the capacity for the assessment of morphological and physiological states and pathological processes in the human body for solving professional tasks (GPC – 9)	Knows	OA-1 Interview	Credit answers 1 semester -1-10
	Module 2. Topical issues of ultrasound diagnostics (USD)		Able to	PW-1 Test	PW-1 Test
			Masters	OA-3 Report	OA-2 Colloquium
	Module 1. Topical issues of radiology	the readiness to collect and to analyze patient complaints, data of its history, the results of laboratory, instrumental, postmortem and other examinations to recognize the incidence or the absence of diseases (PC – 5)	Knows	OA-1 Interview	Credit answers 1 semester -1-10
	Module 2. Topical issues of ultrasound diagnostics (USD)		Able to	PW-1 Test	PW-1 Test
			Masters	OA-3 Report	OA-2 Colloquium
	Module 1. Topical issues of radiology	the ability to determining the tactics of patient surveillance with different nosological entities. (PC – 8)	Knows	OA-1 Interview	Credit answers 1 semester -1-10
	Module 2. Topical issues of ultrasound diagnostics (USD)		Able to	PW-1 Test	PW-1 Test
			Masters	OA-3 Report	OA-2 Colloquium
	Module 1. Topical issues of radiology		Knows	OA-1 Interview	Credit answers 1 semester -1-10
	Module 2. Topical issues of ultrasound diagnostics (USD)		Able to	PW-1 Test	PW-1 Test
			Masters	OA-3 Report	OA-2 Colloquium

Control and methodological materials as well as criteria and indicators necessary for the assessment of knowledge and skills, and characterizing the stages of the formation of competencies in the process of mastering the educational program are presented in Appendix 2.

V. LIST EDUCATIONAL LITERATURE AND INFORMATION SUPPORT OF DISCIPLINE

Main literature

1. Radiodiagnostics of the Lumbar Spine / Springer, Berlin, Heidelberg 2016 https://link.springer.com/chapter/10.1007/978-3-642-74679-6_7
2. Trends in radiology and experimental research / Springer International Publishing 2017 <https://link.springer.com/article/10.1186/s41747-017-0006-5>
3. Thoracic Trauma: Interventional Radiology / Springer, Cham 2017 https://link.springer.com/chapter/10.1007/978-3-319-62054-1_13

Additional literature

(paper and electronic issues)

1. Radiomics: the facts and the challenges of image analysis / Springer International Publishing 2018 <https://link.springer.com/article/10.1186/s41747-018-0068-z>
2. Whole-body magnetic resonance imaging (WB-MRI) in oncology: recommendations and key uses / Springer Milan 2018 <https://link.springer.com/article/10.1007/s11547-018-0955-7>

Electronic edition:

1. www.pulmonology.ru online resource devoted to pulmonology.
2. http://www.goldcopd.org Internet resource dedicated to COPD.
3. www.ginasthma.com Internet resource dedicated to bronchial asthma.
4. www.elibrary.ru online library of educational journals, periodicals and scientific literature. Collected electronic textbooks, reference and training manuals. Search by specific topics and branches of knowledge.
5. www.cardiosite.ru Internet library of educational publications on cardiology. Collected electronic textbooks, reference and training manuals.

Multidisciplinary medical resources

Catalogue of medical resources <http://www.medlinks.ru/>

Website "WEB-medicine". Directory professional medical resources
<http://webmed.irkutsk.ru/>

Medical library. Articles on different branches of medicine. <http://rays.boom.ru/>

Russian medical server. Articles on different branches of medicine.
<http://www.rusmedserv.com/>

BMC Medline.ru. Articles on various branches of medicine.
<http://www.medline.ru/>

Medical portal NewDoctor. Articles on different branches of medicine.
<http://www.newdoctor.ru/>

Internet resources recommended for self-study and as an additional source of information.

<http://lib.volgmed.ru>

<http://elibrary.ru> website of the Federal electronic medical library of the Ministry of health

<http://www.scopus.com>

<http://www.studentlibrary.ru>

<http://e.lanbook.com>

<http://www.usclab.ru> website international online community of experts of ultrasonic diagnostics

<http://www.rasudm.org> -website of the Russian Association of ultrasound diagnostics in medicine

http://www.med_edu.ru -medical video portal

Periodicals

1 electronic library system "University library" <http://www.biblioclub.ru/>

2 "Radiology" <http://rentgenolog.net/>

3 Radiology-Practice journal <http://radp.ru>

4 medical imaging journal <http://medvis.ru>

5 Bulletin Of the Russian scientific center of roentgenoradiology
<http://vestnik.ncrr.ru>

6. Radiation diagnosis and medical radiology <http://www.radiomed.ru>

VI. GUIDELINES FOR DEVELOPMENT OF THE DISCIPLINE

The purpose of practical training is to consolidate the knowledge gained by students at lectures, modeling of practical situations, as well as checking the effectiveness of independent work. The practice classes usually includes an oral questioning on practical classes. This reveals the degree of knowledge of the material of the lecture course, basic textbooks, knowledge of current problems and the current situation in the modern educational space. Further, the ability of students to apply their theoretical knowledge to solving practical problems is revealed.

Preparation for practical classes is advisable to start with a repetition of the material of lectures. It should be kept in mind that the lecture course is limited in time and does not allow the lecturer to consider in detail all aspects of the issue under study. Therefore, it is required to expand knowledge both theoretical and practical. At the same time, lectures provide a good guide for finding additional materials, as they set a certain structure and logic for studying a particular issue.

In the course of independent self-work in the first place it is necessary to study the material presented in the recommended Department and/or teacher of educational literature and monographs. Students should pay attention to the fact that the library list includes not only basic textbooks, but also more in-depth sources on each topic of the course. Consistent study of the subject allows the resident to form a stable theoretical base.

An important part of the preparation for practical training is the work with scientific and analytical articles, which are published in specialized periodicals. They allow you to broaden your horizons and get an idea of current problems, possible ways to solve them and/or trends in the study area.

VII. LIST OF INFORMATION TECHNOLOGIES AND SOFTWARE

The location of the computer equipment on which the software is installed, the number of jobs	List of licensed software
<p>Multimedia auditorium Vladivostok Russian island, Ayaks 10, building 25.1, RM. M723 Area of 80.3 m2 (Room for independent work)</p>	<p>Windows Seven enterprise SP3x64 Operating System Microsoft Office Professional Plus 2010 office suite that includes software for working with various types of documents (texts, spreadsheets, databases, etc.); 7Zip 9.20 - free file archiver with a high degree of data compression; ABBYY FineReader 11 - a program for optical character recognition; Adobe Acrobat XI Pro 11.0.00 - software package for creating and viewing electronic publications in PDF; WinDjView 2.0.2 - a program for recognizing and viewing files with the same format DJV and DjVu.</p>

In order to provide special conditions for the education of persons with disabilities all buildings are equipped with ramps, elevators, lifts, specialized places equipped with toilet rooms, information and navigation support signs.

VIII. MATERIAL AND TECHNICAL MAINTENANCE OF DISCIPLINE

<p>Roentgenology, Radiodiagnostics</p>	<p>Monoblock Lenovo C360G-i34164G500UDK; projection Screen Projecta Elpro Electrol, 300x173 cm; Multimedia projector, Mitsubishi FD630U, 4000 ANSI Lumen 1920 x 1080; Flush interface with automatic retracting cables TLS TAM 201 Stan; Avervision CP355AF; lavalier Microphone system UHF band Sennheiser EW 122 G3 composed of a wireless microphone and receiver; Codec of videoconferencing LifeSizeExpress 220 - Codeonly - Non-AES; Network camera Multipix MP-HD718; Two LCD panel, 47", Full HD, LG M4716CCBA; Subsystem of audiocommentary and sound reinforcement; centralized uninterrupted power supply</p> <p>Medical center of FEFU Installation for x-ray diagnostics Computer tomograph Magnetic resonance imaging Positron emission tomograph Ultrasound machines</p> <p>State Autonomous health care institution "Primorsky regional diagnostic center of specialized types of medical care", Vladivostok.</p>	<p>Multimedia auditory</p> <p>690922, Primorsky Krai, Vladivostok, island Russian, the Saperny Peninsula, Ajax, 10,</p>
--	---	---

Clinical bases:

Medical center of the Federal state autonomous educational institution of higher education "Far Eastern Federal University»;

State Autonomous health care institution "Primorsky regional diagnostic center of specialized types of medical care", Vladivostok.

Medical center "Diamed", Vladivostok



MINISTRY OF EDUCATION AND SCIENCE OF THE RUSSIAN FEDERATION
Federal state autonomous educational institution
of higher education
« Far Eastern Federal University »
(FEFU)

SCHOOL OF BIOMEDICINE

**TRAINING AND METHODOLOGICAL SUPPORT OF INDEPENDENT
WORK OF STUDENTS**
on discipline «Radiology, radiation diagnostics»
Direction of training (specialty) 31.05.01 General medicine
Form of training: full-time

Vladivostok
2016

Independent self-work includes:

1. library and homework with educational literature and lecture notes,
2. preparation for practical classes,
3. performing individual tasks
4. preparation of essays
5. preparing for test and control interview (test)

The order of performance of independent work by students is defined by the schedule of performance of independent self-work on discipline.

Schedule of independent self-work on discipline,

3 semester

No.	Date/deadline	Type of independent self-work	Approximate standards of execution time	Form of control
X-ray				
1	1-4 week	Essay Individual task	4 hours	OA-3-Report
2, 3	2 week	Home task	2 hours	Conspect notes
4,5,6	3, 4 week	Home task	2 hours	Conspect notes
7,8,9,	5,6 week	Home task	2 hours	Conspect notes
10, 11	7 week	Home task	2 hours	Conspect notes
12	8 week	Presentation on the essay topic	2 hours	POA-3-Report
13	9 week	Home task	4 hours	OA-1-Interview PW-1 - Test
Ultrasound diagnostics				
1	1 week	Individual task	2 hours	Report Test control
2	2week	Home task	2 hours	Conspect notes Test control
3	3 week	Home task	2 hours	Conspect notes Test control
4	4 week	Home task	2 hours	Conspect notes Test control
5	5 week	Presentation on the essay topic	2 hours	POA-3-Report, presentation
6	6 week	Presentation on the essay topic	2 hours	POA-3-Report, presentation
7	7 week	Home task	1 hour	Conspect notes
8	8 week	Home task	1 hour	Conspect notes

9	9 week	Home task	4 hours	OA-1-Interview PW-1 - Test
---	--------	-----------	---------	-------------------------------

Topics of reports and essays (presentations)

There are 36 hours of independent work in the discipline.

Within these hours is the 2 essay on the proposed themes (radiology and ultrasound).

Essays

1. X-ray diagnostics of inflammatory diseases of the bronchopulmonary system.
2. X-ray diagnostics of lung cancer.
3. Radiologic diagnosis of diseases of the lungs and mediastinum.
4. Radiologic diagnosis of heart diseases.
5. Angiography. Radiologic diagnosis of the blood vessel disorders.
6. X-ray diagnosis of the digestive system diseases.
7. X-ray diagnostics of diseases of esophagus and stomach.
8. X-ray diagnostics of intestinal diseases.
9. X-ray diagnostics of inflammatory diseases of bones and joints.
10. X-ray diagnostics of benign and malignant bone tumors.
11. X-ray diagnosis of osteoporosis.
12. X-ray diagnostics of diseases of the bone and joint system.
13. X-ray diagnosis of spine disorders.
14. X-ray diagnosis of diseases of the skull and brain.
15. Radiation diagnosis of breast diseases.
16. Radiation diagnosis of the endocrine system diseases.
17. X-ray diagnostics of pulmonary tuberculosis.
18. X-ray diagnostics of osteochondrosis.
19. Differential x-ray diagnostics of destructive pneumonia.
20. X-ray diagnostics of arthritis.
21. X-ray diagnostics of fibrosing alveolitis.

22. X-ray diagnosis of osteosarcoma.
23. X-ray diagnosis of sarcoidosis.
24. X-ray diagnosis of acute pneumonia.
25. X-ray diagnostics of hiatal hernias.
26. X-ray diagnosis of gastric cancer.
27. X-ray diagnostics of tuberculosis complications.
28. CT-diagnosis of brain tumors.
29. X-ray diagnostics of congenital pathology of spine.
30. X-ray diagnostics of congenital pathology of brain.
31. Liver fat degeneration. Steatosis of pancreas.
32. Cholecystitis: acute and chronic (stone-free, stone). Choledocholithiasis.
33. Acute and chronic pancreatitis. The ultrasound picture.
34. Form of kidneys and its variants. Ultrasound image of unmodified parenchyma and Cup-pelvis-plating system
35. Anomalies of kidney and ureter
36. Acute and chronic pyelonephritis. The ultrasound picture.
37. Urolithiasis.
38. Hydronephrosis.
39. Nephroptosis.
40. Vascular diseases of the kidney.
41. Bladder tumors. Benign. Malignant.
42. Atherosclerotic lesions of the aorta.
43. Inferior vena cava thrombosis.
44. Ultrasonic diagnosis of heart tumors.
45. Ultrasound diagnosis of pericardial diseases.
46. Ultrasonic diagnosis of diseases of the myocardium.
47. Ultrasonic diagnosis of diseases of the endocardium.
48. CHD. Coarctation. Ebstein's Anomaly.
49. CHD. Fallot's Disease.
50. CHD. Defects of the interventricular and interatrial septa. Open aortic duct.

51. Minor surgical interventions under control of ultrasound.
52. Puncture biopsy under ultrasound control.
53. Drainage of the cavity under ultrasound control. Determination of indications

Guidelines for writing and design of an essay (presentation)

Essay is a creative activity of the student reproducing in its structure the research activities to solve theoretical and applied problems in a particular branch of scientific knowledge. That is why the course certification work is an essential component of the educational process in higher education.

The essay is a model of scientific research, independent self-work in which a student solves a problem of a theoretical or practical nature, applying the scientific principles and methods of a given branch of scientific knowledge. The result of this scientific search may have not only subjective, but also objective scientific novelty, and therefore can be presented for discussion by the scientific community in the form of a scientific report or presentation at scientific-practical conferences, as well as in a form of research article.

Essay involves the acquisition of skills for building business cooperation, based on ethical standards of scientific activity. Purposefulness, initiative, disinterested cognitive interest, responsibility for the results of their actions, conscientiousness, competence - personality traits that characterize the subject of research activities corresponding to the ideals and norms of modern science.

The essay is an independent educational and research activity of the student. The teacher assists in a consultative manner and assesses the process and the results of the activity. Teacher provides an approximate topic of the essay work, specifies the problem and topic of research with a student or intern, helps to plan and organize research activities, assigns time and a minimum number of consultations.

The teacher receives the text of the essay for verification at least ten days before the defense.

Generally there is a certain structure of the essay, the main elements of which in order of their location are the following:

1. Title page.
2. Goal.
3. Table of Contents
4. List of abbreviations, symbols and terms (if necessary).
5. Introduction.
6. Main part.
7. Conclusion.
8. Reference list.
9. Appendixes.

The title page contains educational institution, graduating department, author, teacher or supervisor, research topic, place and year of the essay.

The title of the essay should be as short as possible and fully consistent with its content.

The table of contents (content) reflects the names of the structural parts of the essay and the pages on which they are located. The table of contents should be placed at the beginning of work on one page.

The presence of a detailed introduction - a mandatory requirement for the abstract. Despite the small volume of this structural part, its preparation causes considerable difficulties. However, this is a qualitatively executed introduction that is the key to understanding the entire work, which testifies to the professionalism of the author.

Thus, the introduction is a very crucial part of the essay. The introduction should start with a justification of the relevance of the chosen topic. As applied to the essay, the concept of "relevance" has one feature. From how the author of the essay can choose a topic and how correctly he understands and evaluates this topic from the point of view of modernity and social significance, characterizes his scientific maturity and professional preparedness.

In addition, in the introduction it is necessary to isolate the methodological basis of the essay, name the authors, whose works constituted the theoretical basis of the study. A review of the literature on the topic should show the author's thorough acquaintance with special literature, his ability to systematize sources, critically examine them, highlight the essential and determine the most important in the up-to-date state of knowledge of the topic.

The introduction reflects the importance and relevance of the chosen topic, defines the object and subject, purpose and objectives, and the chronological framework of the study.

The introduction ends with a statement of the general conclusions about the scientific and practical significance of the topic, the degree of its knowledge and sources, and the hypothesis being put forward.

The main part describes the essence of the problem, reveals the topic, determines the author's position, factual material is given as an argument and for display of further provisions. The author must demonstrate the ability to consistently present the material while analyzing it simultaneously. Preference is given to the main facts, rather than small details.

The essay ends with the final part called "conclusion". Like any conclusion, this part of the essay serves as a conclusion due to the logic of the study which is a form of synthesis accumulated in the main part of scientific information. This synthesis is a consistent, coherent presentation of the results obtained and their relation to a common goal and specific tasks set and formulated in the introduction. At this place there is a so-called "output" knowledge, which is new in relation to the original knowledge. The conclusion may include suggestions of practical matter, thereby increasing the value of theoretical materials.

So, the conclusion of the essay should contain: a) presents the conclusions of the study; b) theoretical and practical significance, novelty of the essay; c) indicated the possibility of applying the results of the study.

After conclusion it is acceptable to place the reference list of the literature used throughout. This list is one of the essential parts of the essay and reflects the independent creative work of the author of the essay.

The list of sources used is placed at the end of the work. It is made either in alphabetical order (by the name of the author or the name of the book), or in the order in which the references appear in the text of the prepared work. In all cases, the full title of the work, the names of the authors or the editor of publication are indicated if the writing team involved a group of authors, data on the number of volumes, the name of the city and publisher in which the work was published, year of publication, number of pages.

Reference work should be presented in a form of printed essay and oral presentation

Evaluation criteria for essays.

The stated understanding of the essay as a holistic copyright text defines the criteria for its evaluation: the novelty of the text; the validity of the source choice; the degree of disclosure of the issue essence; compliance with the requirements for registration.

Essay novelty: a) the relevance of the research topic; b) novelty and independence in the problem formulation, formulation of a new aspect of the well-known problem in the establishment of new connections (interdisciplinary, intra-subject, integration); c) ability to work with research and critical literature, systematize and structure research material; d) the appearance of the author's position, independence of assessments and judgments; d) stylistic unity of the text, the unity of genre features.

The degree of disclosure of the question essence: a) the plan compliance with an essay; b) compliance with the content of topic and plan of an essay; c) completeness and depth of knowledge on the topic; d) the validity of the methods

and techniques of work with the material; e) ability to generalize, draw conclusions, compare different points of view on one issue (problem).

The validity of the source choice: a) evaluation of the used literature: whether the most famous works on the research topic are involved (including recent journal publications, recent statistics, reports, references, etc.)

Compliance with the requirements for registration: a) How true are the references to the used literature, quotes; b) assessment of literacy and presentation culture (including spelling, punctuation, stylistic culture), knowledge of terminology; c) compliance with the requirements for the volume of essay.

The reviewer should clearly state the remarks and questions, preferably with references to the work (possible on specific pages of the work), to research and evidence that the author did not take into account.

The reviewer may also indicate: whether student has addressed the topic earlier (essays, written works, creative works, olympic works, etc.) and whether there are any preliminary results; how the graduate has conducted the work (plan, intermediate stages, consultation, revision and processing of the written or lack of a clear plan, rejection of the head recommendations).

The student submits an essay for review no later than a week before the defense. The reviewer is the teacher. Experience shows that it is advisable to acquaint the student with the review a few days before the defense. Opponents are appointed by the teacher from the students. For an oral presentation a student needs about 10–20 minutes (approximately as long as he answers with tasks for the exam).

Grade 5 is given if all the requirements for writing and defending an essay are fulfilled: the problem is indicated and its relevance is justified, a brief analysis of different points of view on the problem under consideration is made and one's own position is logically presented, conclusions are formulated, the topic is fully disclosed, the volume is met, external requirements are met design, given the correct answers to additional questions.

Grade 4 is given if the basic requirements for the essay and its defense are met, but there are some shortcomings. In particular, there are inaccuracies in the presentation of the material; or there is no logical sequence in the judgments; not sufficient volume of the essay; there are omissions in the design; additional questions for the defense are accompanied with incomplete answers.

Grade 3 is given if there are significant deviations from the requirements for referencing. In particular: the topic is covered only partially; factual errors in the content of an essay or when answering additional questions; there is no output c.

Grade 2 - the topic of an essay is not disclosed, a significant misunderstanding of the problem is found.

Grade 1 - student's essay is not presented.



MINISTRY OF EDUCATION AND SCIENCE OF THE RUSSIAN FEDERATION
Federal state autonomous educational institution
of higher education
« Far Eastern Federal University »
(FEFU)

SCHOOL OF BIOMEDICINE

ASSESSMENT FUND
on discipline «Radiology, radiation diagnostics»
Direction of training (specialty) 31.05.01 General medicine
Level of education (specialty)
Form of training: full-time

Владивосток
2016

Passport of assessment fund

Completed in accordance with the Regulations on the Funds of Evaluation Assets of Educational Programs of Higher Education - Bachelor's Programs, Specialties, FEFU Magistrates, approved by order of the Rector No. 12-13-850 of May 12, 2015.

Competence and its code	Stages of competence formation	
- the capacity for the assessment of morphological and physiological states and pathological processes in the human body for solving professional tasks (GPC – 9)	Knows	Methods of implementation of set of measures aimed at the preservation and promotion of health, methods of assessment of natural and social environmental factors in the development of human diseases, forms and methods of sanitary and educational work;
	Able to	Assess the causes and conditions of the induction and development of diseases in humans; to assess the natural and social factors of the environment in the development of human diseases; to search for solutions to various problems in unusual situations, to carry out sanitary and educational work with the population and patients;
	Masters	Methods of assessment of natural and social environmental factors in the development of human diseases; the basics of preventive measures to prevent diseases; the principles of sanitary and educational work on hygienic issues,
the readiness to collect and to analyze patient complaints, data of its history, the results of laboratory, instrumental, postmortem and other examinations to recognize the incidence or the absence of diseases (PC – 5)	Knows	General and special research methods in the main sections of therapy; basics of ultrasound and methods of radiation diagnostics in various sections of medicine.
	Able to	obtain information about the development and course of the disease; to identify general and specific radiological and US signs of the disease; to assess the severity of the patient's condition; to determine, interpret the data.
	Masters	Skills that allow to establish a diagnosis based on the results of X-ray and US methods in the most common therapeutic diseases;
- the ability of determining the patient's basic pathological conditions , symptoms, syndromes, diseases in	Knows	General and special research methods in the main sections of therapy; basics of ultrasound and methods of radiation diagnosis in various sections of medicine.

Competence and its code	Stages of competence formation	
accordance with the International Statistical Classification of Diseases and problems related to health , the 10th review. (PC – 6)	Able to	Obtain information about the development and course of the disease; to identify general and specific radiological and US signs of the disease; to assess the severity of the patient's condition; to determine, interpret the data.
	Masters	Skills that allow to establish a diagnosis based on the results of X-ray and US methods in the most common therapeutic diseases;

Control of the course goal achievement

No.	Controlled sections / topics of disciplines	Codes and stages of the formation of competencies	Assessment tools - name		
			Current control		Intermediate certification
	Module 1. Topical issues of radiology	the ability and willingness to use social methods of data collection and analysis of medical and statistical information on health indicators of population (PC – 4)	Knows	OA-1 Interview	Credit answers 1 semester -1-10
	Module 2. Topical issues of ultrasound diagnostics (USD)		Able to	PW-1 Test	PW-1 Test
			Masters	OA-3 Report	OA-2 Colloquium
	Module 1. Topical issues of radiology	- the readiness to collect and to analyze patient complaints, data of its history, the results of laboratory, instrumental, postmortem and other examinations to recognize the incidence or the absence of diseases (PC – 5)	Knows	OA-1 Interview	Credit answers 1 semester -1-10
	Module 2. Topical issues of ultrasound diagnostics (USD)		Able to	PW-1 Test	PW-1 Test
			Masters	OA-3 Report	OA-2 Colloquium
	Module 1. Topical issues of radiology	the ability to determining the	Knows	OA-1 Interview	Credit answers 1 semester -1-10

	Module 2. Topical issues of ultrasound diagnostics (USD	tactics of patient surveillance with different nosological entities. (PC – 8)	Able to	PW-1 Test	PW-1 Test
			Masters	OA-3 Report	OA-2 Colloquium

Competence and its code	Stages of competence formation		criteria	indicators	points
- the capacity for the assessment of morphological and physiological states and pathological processes in the human body for solving professional tasks (GPC – 9)	Knows (threshold level)	Implementation methods of a set of measures aimed at the preservation and promotion of health, methods of assessment of natural and social environmental factors in the development of human diseases with a deeper understanding of the nature of the studied phenomena and relationships; causes of pathological processes in the body, the mechanisms of their development and clinical manifestations; principles; forms and methods of sanitary and educational work;	Prevention methods of disease conditions, preservation and promotion of health, taking into account the influence of factors of the natural and social environment; sanitary and educational work;	Formed structured systematic knowledge of preventing methods of disease conditions, preservation and promotion of health, taking into account the influence of factors of the natural and social environment; methods of sanitary and educational work;	65-71
	Able to (advanced)	To assess the causes and conditions of induction and development of diseases in humans; to assess the natural and social factors of the environment in the development of human diseases; to carry out sanitary and educational work on hygienic issues, to search for solutions to various problems in unusual situations, to carry out sanitary and	Ability to analyze and make conclusions about the causes and conditions of occurrence and development of human diseases, taking into account the influence of factors of the natural and social environment; to carry out sanitary and educational work;	Ready and able to analyze and make conclusions about the causes and conditions of occurrence and development of diseases in humans, taking into account the influence of factors of the natural and social environment; to carry out sanitary and educational work;	71-84

		educational work with the population and patients;			
	Masters (high)	Methods of assessment of natural and social environmental factors in the development of human diseases; the basics of preventive measures to avoid diseases; sanitary and educational work on hygienic issues,	Analytical skills regarding influence of ambient social factors on development of diseases at the any person; conducting sanitary and educational work on prevention and prevention of diseases	Ability to confidently analyze the impact of social environmental factors on the development of human diseases; to carry out sanitary and educational work on the prevention and prevention of diseases	85-100
the readiness to collect and to analyze patient complaints, data of its history, the results of laboratory, instrumental, postmortem and other examinations to recognize the incidence or the absence of diseases (PC – 5)	Knows (threshold level)	X-ray and diagnostic methods in various diseases	Knowledge of special radiological and radiological diagnostic methods in the basic areas of therapy;	Formed structured systematic knowledge of the X-ray and radiodiagnostic methods in the main sections of therapy; basis for the use of radiology and radiodiagnostic methods in the different sections of pediatrics	65-71
	Able to (advanced)	Get information about the development and course of the disease; apply radiological and radiological methods of diagnosis, to identify common and specific signs of the disease; to assess the severity of the patient's condition; to determine, interpret the data;	The ability to use medical information resources, use radiological and radiological methods of examination to identify signs of the disease, assess its severity, to interpret the data	Ready and able to use medical information resources, use radiological and radiological methods to detect signs of the disease, assess its severity, and interpret the data obtained	71-84
	Masters (high)	Formed skills allowing to establish the diagnosis and provide for the most common diseases;	Diagnostics skills of common therapeutic diseases;	Ability to confidently analyze the patient's examination data and make a diagnosis based on them in the most common therapeutic diseases;	85-100
the ability of determining the patient's basic pathological conditions ,	Knows (threshold level)	General and special radiological and radiation diagnostic methods in the main areas of therapy, modern	Knowledge of general and special radiological and radiation diagnostics methods in the main sections of therapy,	Formed structured systematic knowledge of general and special radiological and methods of radiation	65-71

symptoms, syndromes, diseases in accordance with the International Statistical Classification of Diseases and problems related to health , the 10th review. (PC – 6)		technologies and equipment	modern technologies and equipment	diagnostics of the main sections of therapy, modern technologies and equipment	
	Able to (advanced)	To use X-ray and radioation diagnostic methods the patient has signs of disease; to determine the indications for hospitalization of the patient, to determine its urgency	Skills to apply radiological and radiation methods of diagnostics in a patient, to identify common and specific signs of the disease; determine the indications for hospitalization;	Ready and able To apply radiological and radiation diagnostic methods in a patient, to identify common and specific signs of the disease; determine the indications for hospitalization of the patient	71-84
	Masters (high)	Skills to establish the diagnosis and conduct the necessary X-ray examination, in diseases in accordance with the qualification characteristics	Skills of diagnosis, scheduling and conducting necessary X-ray diagnostics for diseases of the in accordance with the qualification characteristics	Ability to confidently diagnose, prescribe and carry out the necessary X-ray and radiation diagnosis of diseases in accordance with the qualification characteristics	85-100

Questions for assessment of preliminary competencies

1. Organization of radiodiagnostic service according to the legislation of the Russian Federation.
2. Organization of departments (offices) of radiology: requirements, documentation.
3. Digital radiography: physical and technical basis, advantages, types of devices.
4. Physical and technical basis of X-ray computer tomography.
5. Physical and technical basis of magnetic resonance imaging. Indications and contraindications to MRI.
6. The relationship of radiology with other methods of radiation diagnosis. Hybrid technologies of radiation diagnostics.
7. Measures for radiation protection of patients and personnel during X-ray examinations. Local control.
8. Differential X-ray semiotics of various forms of pulmonary tuberculosis.
9. Pulmonary hemodynamics as an indicator of the functional ability of the myocardium.
10. X-ray computed tomography in lung pathology.
11. X-ray examination of the CVS.
12. X-ray computed tomography in the differential diagnosis of pancreatitis.

Control tests

Control tests are purposed for students studying the discipline "Psychiatry." Tests are necessary for both the control of knowledge in the process of the current intermediate certification, and for assessment of knowledge, the result of which can be the set of credit.

Working with tests student is proposed to choose one answer from three to four given. At the same time tests are unequal in their complexity. There are tests that contain several options for correct answers among the ones proposed. Student is to specify all the correct answers.

Tests are designed for both individual and collective decision work. They can be used in the process of classroom and independent work. Selection of tests necessary for the control of knowledge in the process of intermediate certification is carried out by each teacher individually.

The results of the test tasks are assessed by the teacher using a five-point scale for issuing attestation or on the "test" system - "no test". Grade "excellent" is set if the number of correct answers is more than 90% of the tests proposed by the teacher. Grade "good" is set if the number of correct answers is more than 70% of tests. Grade "satisfactory" is set if the number of correct answers is 50% of the tests proposed for student.

Examples of testing tasks

Instruction: choose one correct answer:

1. PACS is:

- A. electronic card of the patient;
- B. image processing software;
- C. variety of automated workplace of the doctor;
- D. medical image archiving and transmission system;
- E. program - electronic assistant of the doctor.

The answer is D.

2. Which of the presented computer networks can be considered as global:

- A. radiology information system (hereinafter - RIS);
- B. Internet;
- C. Hospital information system (hereinafter - HIS);
- D. teleradiological network, uniting several medical organizations;
- E. the computer network of Department of radiology.

The answer is B.

3. The annual effective dose of radiation during the verification of medical X-ray and scientific research of healthy individuals should not exceed:

- A. 0.5 mSv;
- B. 1.0 mSv;
- C. 2.0 mSv;
- D. 5.0 mSv;
- E. Of 0.5 SV.

The answer is B.

4. Tuberculosis of intrathoracic lymph nodes is characterized by:

- A. A symmetrical lesion of the nodes of the lungs;
- B. The defeat of the nodes inside the front mediastinum;
- C. Lesions of the nodes of the posterior mediastinum;
- D. Asymmetric lesion of the nodes of the roots of the lungs;
- E. Pleural overlays.

The answer is D.

5. Cystic kidney formation type 1 according to Bosniak's classification is matching:

- A. A simple cyst;
- B. Cysts with liquid or hemorrhagic contents;
- C. Benign cyst with 1 or more chambers;
- D. cyst with soft tissue component;

E. Cyst more than 3cm with a large number of thin partitions and calcification of the walls.

The answer is A.

6. Instructions: choose the correct answer according to the scheme:

A. If the correct answers are 1, 2, and 3;

B. If the correct answers are 1 and 3;

C. If the correct answers are 2 and 4;

D. If the correct answer is 4;

E. If the correct answers are 1, 2, 3 and 4.

7. The most typical manifestations of rheumatoid arthritis joint syndrome:

1. acute monoarthritis of the 1st metatarsophalangeal joint;

2. multiple symmetrical arthritis of small and large joints;

3. persistent arthralgias in the area of the hip joint;

4. morning stiffness of the joints of the hands.

The answer is B.

Instructions: choose all the correct answers

8. For chronic sinusitis the following CT characteristics are typical:

A. increased volume of the paranasal sinus;

B. thickening of the walls of the sinus;

C. thinning of sinus walls;

D. proliferative changes in the mucosa;

E. accumulation of exudate against the background of minor proliferative changes in the mucosa.

The answer is B.

9. Radiological signs of free fluid in the abdominal cavity

A. the extension of the lateral channels is the lack of anatomic detail;

B. "Air" with rounded ends;

C. triangular, semilunar and stripe-shaped dimming between swollen intestinal loops;

D. shift of the darkening in the underlying parts of the abdominal cavity with a change in the position of the patient;

E. displacement of the diaphragm dome.

Answers: A, B,

10 instruction: match the positions shown in the indicated columns. For each letter component in the left column, select the numbered element in the right column. Each numbered item in the right column can be selected once, more than once, or not selected at all:

Joint diseases	Most typical radiological alterations
A. rheumatoid arthritis B. ankylosing spondylitis C. deforming arthrosis D. psoriatic arthropathy E. gout	1. sacroiliitis, calcification of spinal ligaments; 2. cartilaginous osteosclerosis, osteophytes; 3. destructive arthrosis, “punches; 4. osteolysis of distal phalanges; 5. marginal bone erosion of epiphysis

Answers A-5; B-1; C-2; D-4; E-3.

Clinical diagnosis	X-ray signs
A. Pancreatic cancer	1. gland enlargement, infiltration of peripancreatic fiber, liquid collectors;
B. Insulinoma	2. vascularity type contrast enhancement;
C. Chronic pancreatitis	3. invasion of fiber around the superior mesenteric artery, liver metastases, lymphadenopathy;
D. Pancreatic cystadenoma	4. hypervascular type of contrast enhancement;
E. Acute pancreatitis	5. multiple calcifications, possible dilation of the Wirsung duct

Answers: A-3; B-4; C-5; D-2; E-1.

11. Instruction: set the correspondence between the positions presented in the indicated columns. For each letter component in the left column, select the numbered element in the right column. Each numbered item in the right column can be selected once, more than once, or not selected at all.

Type of the liver examination	Parameter
A. gray-scale visualization	1. Echogenicity
B. spectral Doppler	2. Structure
C. color Doppler visualization	3. Average linear velocity of blood flow
D. elastography	4. Flow chart
	5. Angle Alpha
	6. Compressibility
	7. Density
	8. Distal attenuation

Answer

- A - 1,2,8
- B - 3,5
- C - 4
- D - 6

12. The echogenicity of unmodified tissue of the liver:

- a. hyperechogenic;
- b. slightly lower echogenicity of the cortical substance of the kidney unchanged;
- c. exactly corresponds to the echogenicity of the cortical substance of the unchanged kidney;
- d. slightly higher than the echogenicity of the cortical substance of the unchanged kidney;
- e. comparable to the echogenicity of the cortical substance of the unchanged kidney.

13. Echographic diagnosis of liver cysts is based on:

- a. definition of anechoic rounded formations with clear contours located in the liver parenchyma
- b. determination of solid structures in the liver parenchyma
- c. determination of inhomogeneous formations of polymorphic echostructure with clear contours

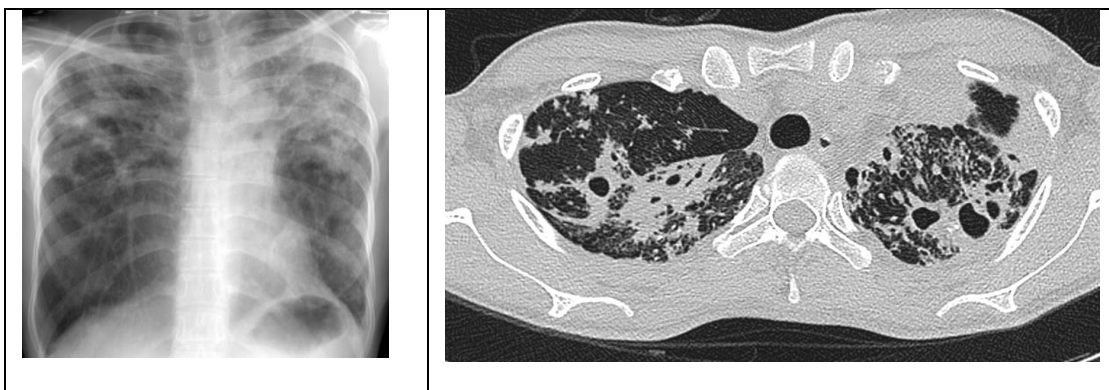
d. determination of infiltrative changes with different degree of density

14. Specify the main echographic signs of pancreatic head cancer:

- a. the contours are uneven, the local enlargement of prostate
- b. detection of focal lesion of the head of the gland
- c. echostructure inhomogeneous head
- d. displacement and compression of vessels
- e. extrahepatic cholestasis, liver metastases
- f. true all
- g. right B, D and e

Examples of case study tasks

Case study task 1. Male 77 years old was delivered to the emergency room by an ambulance. Complaints of cough and intermittent hemoptysis for the last 3 days in the form of streaks of red blood in the sputum. A week ago got fever and during the week the temperature remains 37,5-38,0°C. Does not work, lives alone. Last chest X-ray was performed 5 years ago - without pathology. Haven't seen a doctor since then. Chest X-ray and computed tomography of the lungs were performed in the hospital.



Determine the disease, which can be assumed according to radiography and X-ray computed tomography. Write the protocol of analysis according to the presented copies of pictures.

Instruction: choose one correct answer:

- A. Lung edema

- B. Pulmonary embolism;
- C. Pneumonia;
- D. Central cancer;
- E. Tuberculosis of lungs.

Answer: E.

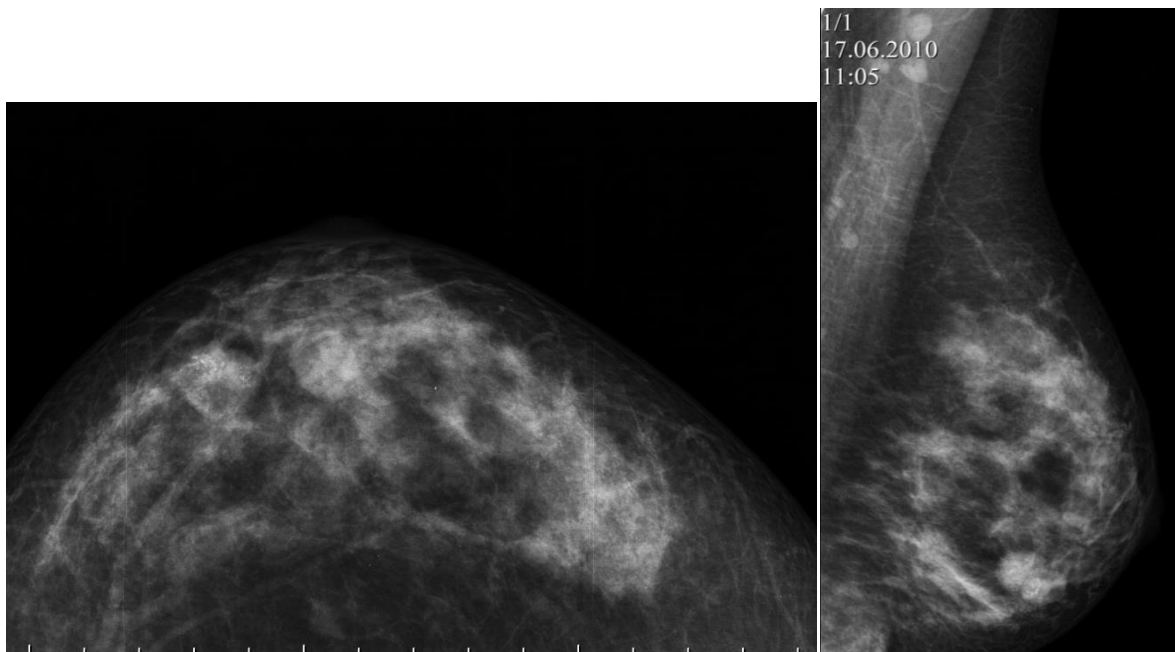
Case study task 2. A 53-year-old woman came for a preventive examination. On ultrasound in the left breast revealed a hypoechoic rounded formation with smooth contours. X-ray mammography was performed. Formulate analytical protocol. Formulate a conclusion.

Instruction: choose one correct answer:

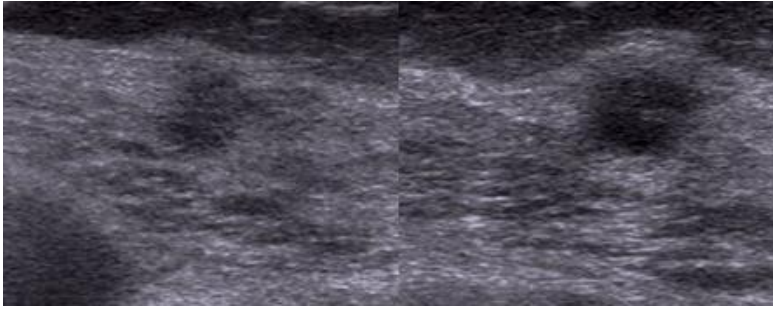
Conclusion according to the study:

- A. Breast cysts;
- B. Fibroadenoma of the breast;
- C. Cystic breast cancer;
- D. Lipoma of the breast;
- E. Nodal mastopathy of the breast.

Answer: B.



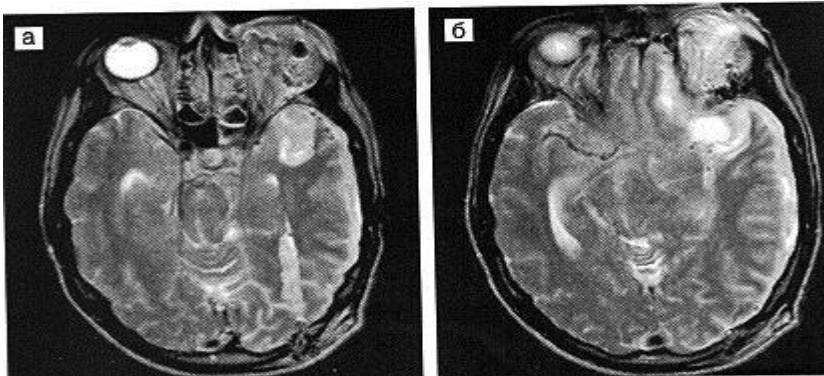
Mammogram of the left breast in craniocaudal and mediolateral projection



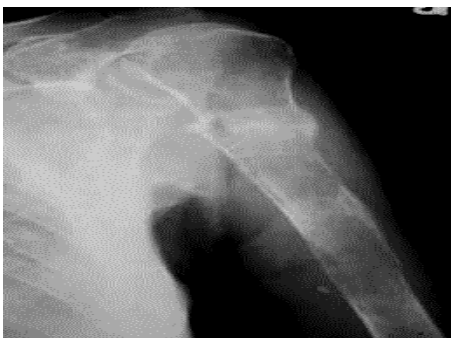Ultrasound of the left breast

Case study task 3

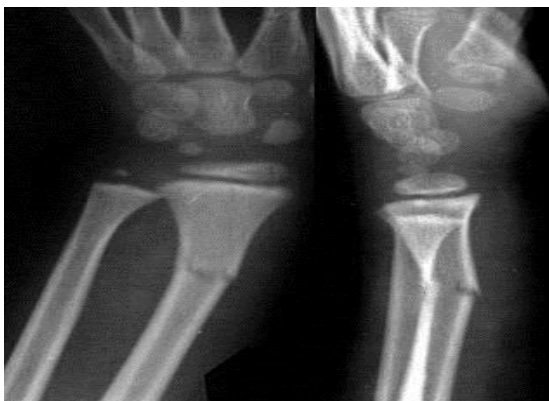Task 1. The figure shows an MRI of a patient with a bullet wound to the skull and brain. Find the wound channel, trace it all the way through, determine which skull bones and brain sections are damaged.



Case study task 4. Watch the radiograph. 1. Specify the methodology and area of study. 2. Projection. 3. Identify pathological changes and characterize them. 4. Formulate a conclusion



Task 3. Specify the methodology and area of study. 2. Projection. 3. Reveal changes. 4. Characterize them. 5. Formulate a conclusion.



Case study task 4

Female, 35 years old.

Complaints of aching back pain, weakness, subfebrile fever. Medical history: described the complaints that have been concerned for three months. Observed in the TB dispensary for five years due to intestinal tuberculosis.

Examination. During the examination, the "buttoned" persistence of the spinous process of one of the lower thoracic vertebrae, pain in palpation of the lower thoracic vertebrae. On radiographs of the spine in a straight projection- paravertebral shadows along Th 9-12, narrowed intervertebral slit Th 10-11, in the lateral projection- anterior wedge-shaped deformation Th 10-11, narrowed intervertebral slit Th 10-11, on the middle lateral tomogram Th 8-12- further revealed subchondral Central lytic destruction of adjacent surfaces Th 10-11. In the study of lungs and blood tests - without pathology.

Your conclusion:

1. Metastases to the vertebrae.
2. Osteoarthritis of the spine.
3. Neurogenic tumor.
4. Tuberculous spondylitis.

Correct answer: tuberculous spondylitis

Case study task 5

Male, 46 years old.

Complaints of severe pain and swelling in the right shin. Anamnesis: 2 weeks since throat angina, the temperature increased again up to 39 degrees, there was pain in the right knee joint, and then swelling of the right shin. For three weeks he took painkillers and antipyretic drugs. In the process treatment short-term improvements were noted.

Examination. The right shin is swollen, the skin is shiny, reddened, hot to the touch, painful with palpation. Enlarged right inguinal lymph nodes up to 1.5 cm. In blood analysis: leukocytosis, stab shift, accelerated ESR.

Radiographs of the right tibia in frontal and lateral projections for the middle third of the diaphysis of the right tibia periostitis lace on the front half, the cortical layer of reduced density, medullary canal is slightly expanded. The volume of soft tissues of the lower leg is increased, the contours of the muscles are not traced.

Your conclusion.

1. Osteoid-osteoma of the right tibia.
2. Tuberculosis.
3. Acute hematogenous osteomyelitis.
4. Ewing sarcoma.

Correct answer: Acute hematogenous osteomyelitis.

Case study task 6

Boy, 3 years.

Complaints of "lump" in the left parietal region of the head, fistula with scant discharge. Anamnesis: mother noticed a swelling on her head while bathing the baby two months ago. Turned to the surgeon who diagnosed the injury, the child was not treated. After 2 months, the fistula opened in the area of swelling. The mother of the child and his older brother are observed in the TB dispensary for five years for pulmonary tuberculosis.

Examination. After removing the bandage in the left parietal area of the tumor, elastic consistency, in the center of which the fistula.

On the radiographs of the skull in two projections: in the left parietal bone lytic destruction of irregular shape 3x5 cm with fuzzy irregular contours, with a sequester in the center in the form of "melting sugar".

Your conclusion.

1. Histiocytosis-X in the left parietal bone
2. Tuberculosis.
3. Epidermoid cyst.
4. Ewing sarcoma.

Correct answer: Tuberculosis

Case study task 7

Female, 41 years old.

Complaints of persistent aching pain in the left shoulder joint. Anamnesis: The pain has bothered for two months, did not increase.

Examination. Movements in the shoulder joints are not limited. No deformities. Soft fabrics are not changed.

On radiographs of the left shoulder joint in two projections in the proximal epimetaphysis of the humerus, there is a rounded lytic destruction with clear contours up to 3 cm in diameter with small calcifications.

Your conclusion:

1. Brody's abscess (chronic osteomyelitis).
2. Codman's tumor (chondroblastoma).
3. Arthrosis of the shoulder joint.
4. Tuberculosis.

The standard answer: Codman's tumor (chondroblastoma).

Case study task 8

Boy, 11 years old.

Complaints of pain in the right half of the chest, swelling over the right clavicle, periodic temperature rise to 38 degrees. Anamnesis: After suffering a sore throat with a pain in the chest, after 2 weeks the swelling above the collarbone was noted. In the analysis of blood – inflammatory changes.

Examination. Swelling without clear boundaries over the right clavicle, painful with palpation.

On chest radiographs in two projections - a large homogeneous round-shaped node occupying the upper third of the right hemitorax, the pulmonary pattern is strengthened under the node. On the "hard" chest x-ray in a direct projection-in the first right edge throughout the small-focal mixed destruction with a linear periosteal reaction along the upper contour of the rib.

Your conclusion:

1. Ewing's sarcoma of the first right rib.
2. Acute hematogenous osteomyelitis.
3. Mediastinal tumor.
4. Tuberculosis

Correct answer: Ewing's Sarcoma of the first right edge

Case study task 9.

Choose the correct answer corresponding to the echocardiographic description:

Patient M., 60 years

Standard measurement:

PJ 24 mm AO 32 mm LP 37 x 57 mm

LV IVS 15 mm 49 mm 14 mm ssi

The calculation of parameters of Central hemodynamics:

BWW LV 117 ml, CSR LV 62 LV UO ml 55 ml MM LV 238g

Index MM LV 143 g/m sq

FV LV by Teicholz 67% (normally more than 60%)

Description of the study:

The walls of the aorta are moderately calcined. Valve flaps are slightly sealed at the edges, movements are correct. Systolic ventricular function is good. The size of the left atrium is slightly dilated. Areas of violation of local contractility is not revealed. Moderate concentric hypertrophy of the left ventricular walls. There is no fluid in the pericardial cavity and pleural cavities.

Of echocardiography: Mild mitral and tricuspid regurgitation. Violation of left ventricular diastolic function type 1 (tissue pulsed Doppler). The data for the presence of pulmonary hypertension not. Systolic pressure in LA = 26 mm Hg.

- a. hypertensive heart;
- b. aortic stenosis;
- c. mitral stenosis;
- d. dilated cardiomyopathy;

Case study task 10 .

Ultrasound examination of the right lobe of the liver revealed for the first time a rounded hyperechogenic homogeneous avascular formation up to 25 mm in size without additional effects. The initial assumption is capillary hemangioma.

Instructions: choose the correct answer:

Further actions based on the ultrasonic method of analysis are as follows:

- A. Monthly dynamic study;
- B. Subsequent studies in 1-1,5 months., 3 months., then - once in 6-9 months.;
- C. Control study once a year;
- D. Dynamic observation can not be carried out, because the tumor must be operated on;
- E. Taking to account the absolute benign character, tumor can not be re-examined.

The answer is B

Case study task 11 .

Ultrasound examination of the kidneys revealed anechogenic formation of round shape with a thin-walled capsule with a homogeneous content, sizes are 1,1x0,8 cm in the lower pole of the right kidney.

Instructions: choose the correct answer:

- A. Angiomyolipoma;
- B. Solitary cyst;
- C. Hemangioma;
- D. Echinococcal cyst;
- E. Abscess.

The answer is B

Case study task 12 .

Patient, 65. He tells about complaints of noise in the head, ears, a sharp decrease in visual acuity.

Color duplex scanning of extracranial BCA revealed heterogeneous atherosclerotic plaque of the extracranial part of the right internal carotid artery with stenosis of 85% and stenosis of bifurcation of the left common carotid artery of 50% in diameter due to hyperechogenic, stable atherosclerotic plaque.

Instructions: choose the correct answer:

Further actions of a doctor based on ultrasonic diagnostics must include:

- A. direction to the angiosurgeon consultation;
- B. monthly dynamic study;
- C. inpatient medical treatment and further observation by a neurologist at the place of residence.

Answer A

Performed using basic knowledge of the discipline

Evaluation criterion:

Passed - a student solved situational task without errors

Not passed - a student could not solve the situational problem

Individual task

An individual task is formed jointly by the student on the topic of the lesson

Evaluation criterion:

Credited – a student has completed an individual task

Not credited - a student was able to execute an individual task

Sample subjects for control questions:

I. X-RAY DIAGNOSIS OF DISEASES OF THE CHEST ORGANS

1. Research methods. Technical specifications. Strengthening of the image.
2. MSCT-anatomy of the chest. Equity and segmental structure. Tracheo-bronchial tree. Lung pattern and roots of the lungs. Pleura. Mediastinum.
3. Anomalies and malformations of the lungs and bronchi. Classification. Anomaly of development. Malformation. Agenesis, aplasia of the bronchial tree, lung. Hypoplasia of the bronchial tree. Bronchopulmonary cysts. Tracheobronchomegaly. Bronchoesophageal fistula. Pulmonary sequestration. Anomalies and malformations of the vascular system. Hypoplasia of the pulmonary artery. Arterio-venous aneurysms and fistulas.
4. Diseases of the trachea. Non-neoplastic diseases. Dislocation and compression of the trachea. Foreign bodies of the trachea. Tracheal tumors are benign and malignant. Differential diagnosis and significance of special methods.
5. Lung tumor. Malignant tumors of the lungs. Central cancer. Peripheral cancer. A rare form of lung cancer. Metastatic lung tumors. Benign tumors of the lungs and bronchi. Intrabronchial epithelial tumors. Extra-bronchial epithelial tumors. Hamartomas. Vascular tumor.
6. Inflammatory diseases of the lungs. Acute inflammatory lung diseases. Primary pneumonia. Acute abscess (including gangrenous). Secondary pneumonia.
7. Chronic suppurative and inflammatory diseases of the lungs and bronchi. Diseases of the bronchi. Lung disease. Complications and outcomes. Emphysema. Pulmonary tuberculosis. Primary tuberculosis complex. Tuberculosis of intrathoracic lymph nodes. Disseminated tuberculosis of the lungs. Focal pulmonary tuberculosis. Infiltrative pulmonary tuberculosis.
8. Diseases of the pleura. Pleurisies. Primary tumors of the pleura. Metastatic lesions of the pleura.
9. Neoplasms of the mediastinum. Benign tumors and cysts. Tumors of the thymus gland. Retrosternal and intrathoracic goiter. Teratodermoid formations. Coelomic cysts of a pericardium. Abdominal-mediastinal lipomas. Neurogenic tumors. Bronchogenic and enterogenic cysts. Fat tumors. Rare tumors and cysts. Differential diagnosis of cardio-diaphragmatic angle formations. Differential diagnosis and significance of special methods. Primary malignant tumors of the mediastinum
10. Diseases of the esophagus. Scarring of the esophagus. Tumors of the

esophagus. Benign tumor. Esophagus cancer. Cardio-esophageal cancer. Varicose veins. Secondary changes and diseases of the esophagus. Fistula the esophagus.

11. Congenital heart defects and vascular malformations. Coarctation. Aortic stenosis.

12. Acquired heart defects. Mitral stenosis. Insufficiency of the mitral valve. Aortic stenosis. Insufficiency of the aortic valve. Combined and combined heart defects.

13. Coronary heart disease. MSCT coronary angiography.

14. Changes in the shape, structure and contractility of the myocardium

15. Complications of coronary heart disease

16. Tumors of the heart. Myxomas. Rhabdomyoma. Sarcomata.

17. Secondary lesions of the myocardium

18. Diseases of the pericardium. Pericarditises. Coelomic cysts of a pericardium. Tumors of the pericardium.

19. Pathological conditions in operated patients. Pleural empyema. Pneumothorax, hydrothorax. The residual cavity. Hematomas. Mediastinitises. Assessment of prostheses (aorta, trachea, esophagus).

II. X-RAY DIAGNOSTICS OF DISEASES OF ABDOMINAL CAVITY AND RETROPERITONEAL SPACE

1. Research methods. Technical specifications. Strengthening of the image.

2. MSCT anatomy: liver, pancreas, spleen, kidneys, diaphragm.

3. Anomalies and malformations of the abdominal cavity and retroperitoneal space.

4. Pancreas. Liver and biliary tract. Spleen. Reins. Aperture. Major vessels.

5. Pathological conditions of the diaphragm. Functional diseases of the diaphragm. Inflammatory diseases of the diaphragm. Tumors and cysts of the diaphragm. Diaphragmatic hernia.

6. Diseases of the liver and biliary tract. Liver disease. Inflammatory disease. Parasitic disease. Tumors. Cysts. Injuries. Diseases of the biliary tract. Inflammatory disease. Tumors. Secondary changes

7. Diseases of the pancreas. Inflammatory disease. Tumors. Cysts.

8. Diseases of the spleen. Parasitic disease. Inflammatory disease. Tumors. Lesions in systemic diseases. Injuries.

9. Pathological conditions of large vessels. Pathological conditions of the aorta. Changes in inflammatory diseases. Aneurysms. Pathological conditions of the inferior Vena cava.

10. Diseases of the stomach and intestines. Assessment of the prevalence and stage of malignant lesions.

11. Diseases of the kidneys, upper urinary tract and adrenal glands. Inflammatory diseases of the kidneys and ureters. Malignant tumors of the kidneys and ureters. Benign kidney tumors. Kidney cysts. Urolithiasis. Hydronephrosis. Vascular diseases of the kidneys and ureters. Adrenal hyperplasia. Cysts of the adrenal glands. Tumors of the adrenal glands.

12. Non-organ diseases of the abdominal cavity and retroperitoneal space. Inflammatory disease. The paranephritis. Abscesses. Retroperitoneal fibrosis. Tumors and cysts. Kidney cancer. Benign tumor. Kidney cysts.

13. Pathological conditions in operated patients. Residual cavity. Abscesses. Postoperative traumatic cysts. Hematomas. Assessment of prostheses (aorta, inferior vena cava).

THE LIST OF QUESTIONS FOR INTERVIEWS (credit)
discipline “Radiology”

1. The history of radiology.
2. Modern directions of digital radiography (fluorography).
3. Criteria of quality of the x-ray image.
4. The essence of x-ray computed tomography. The last generation of CT.
5. The essence of magnetic resonance imaging.
6. Comparative evaluation of x-ray and magnetic resonance computed tomography.
7. Methods of artificial contrast: tasks, principles, names of the method of the choice of contrast agent, the ways of its introduction and speed.
8. Contraindications for MRI.

9. Features of radiation studies in children.
10. Tactics of x-ray examination in case of suspected perforation of the genital organ of the abdominal cavity.
11. Normal pulmonary pattern in the x-ray image, normal criteria, types of pathological adjustment.
12. X-ray diagnostics of bronchial conduction disorders. The reasons for its cause. Degree of violation.
13. Syndrome of the total blackout of pulmonary field: outside and inside the lungs diseases.
14. The syndrome of round shadow of the lung fields, determining the localization and characterization of the pathological process.
15. Syndrome of limited darkening of the pulmonary field. List the diseases manifested by this syndrome.
16. X-ray diagnostics of malignant and benign diseases in the lungs.
17. Diseases of the mediastinal organs, methods of radiation research.
18. Radiation diagnosis of traumatic injuries of the chest cavity.
19. Syndrome mitral configuration of the heart: characteristics of the mitral lesions.
20. Syndrome aortic configuration of the heart: characteristics of the aortic defect.
21. Radiological signs of left ventricular failure.
22. Radiological signs of failure right in the stomach.
23. Radiological signs of cardiogenic pulmonary edema.
24. Anatomical features of the esophagus, methods of x-ray examination.
25. Differential diagnosis of benign and malignant tumors of the esophagus.
26. Methods of examination of the digestive tract.
27. Distinctive features of mechanical and functional intestinal obstruction.
28. X-ray examination of the biliary tract.

29. Radial methods of research of the colon.
30. X-ray signs of ulcerative colitis.
31. Radiological signs of dystopia and nephroptosis.
32. Diagnostic signs of renal colic.
33. The symptom of "white buds", the tactics of the survey.
34. Distinctive features of solitary kidney cyst and polycystic.
35. Differential diagnosis of kidney tumor and tuberculosis.
36. Types of x-ray examination of kidney and urinary tract diseases.
37. Features of localization of a shadow suspicious on a concrement in a bladder and prostate gland.
38. Radiation diagnosis of traumatic injuries of the urinary tract.
39. X-ray diagnostics of focal pulmonary tuberculosis.
40. X-ray diagnostics of infiltrative pulmonary tuberculosis.
41. Tuberculous spondylitis. Diagnostics.
42. Radiological signs of gastric tumor.
43. Radiological signs of malignant tumors of the large intestine.
44. Computed tomography, the principle of imaging, opportunities and disadvantages.
45. Radiological signs of gastric ulcer.
46. Methods of fluoroscopy, advantages and disadvantages, indications for use.
47. Normal X-ray of the heart. X-ray semiotics of diseases.
48. Radioisotope diagnostics, the principle of obtaining diagnostic information, opportunities and disadvantages.
49. Digital methods of research in radiology.
50. Rontgenanalytik stomach cancer.
51. Normal X-ray anatomy of the thoracic cavity.
52. X-ray methods for determining the localization of foreign bodies of the gastrointestinal tract.
53. Clinical and radiological forms of pulmonary tuberculosis.

54. X-ray methods for the investigation of the urogenital area.
55. Radiological signs of colon cancer.
56. Fluorography, its varieties, possibilities, disadvantages.
57. Radiological signs of central lung cancer.
58. Radiological methods of examination of the colon.
59. Radiation diagnosis of diseases of the liver and biliary tract.
60. The method of magnetic resonance imaging, the basic physical principles.
61. Methods of excretory urography, indications for use.
62. Radiation diagnosis of urolithiasis.
63. Radiological signs of myocarditis, pericarditis.
64. The technique of angiocardigraphy. Indications for use.
65. Radiological signs of peripheral lung cancer
66. Modern methods of radiation diagnosis(X-ray computed tomography, digital radiography, magnetic resonance imaging.
67. Indications for X-ray examination and contrast examination in radiology.
68. Indications for the main and special methods of research in diseases of the respiratory system.
69. Indications for the main and special methods of research in diseases of the cardiovascular system.
70. Indications for the main and special methods of research in diseases of the gastrointestinal tract.

Indicative topics of questions for the interview in ultrasound diagnostics

1. Change in the velocity of the ultrasonic wave depending on the density of the medium.
2. What is the reverb artifact in ultrasound investigation, how it can interfere and help in determining the type of pathological lesion.

3. The artifact of distal pseudo-amplification of the ultrasonic signal, at which pathological formations usually occurs.
4. Distal attenuation of the ultrasonic signal in diffuse liver disorder, for which liver disease condition this artifact is most characteristic.
5. List the side effects of ultrasonic wave propagation in organs and tissues.
6. Formulate the basic rules for the prevention of complications of minimally invasive interventions under ultrasound control.
7. Specify the main features of the most common artifacts of ultrasound scanning and how to correct them.
8. Give a description of the correct sequence of actions to obtain the correct diagnostic information during the complex (color and spectral) Doppler vascular examination.
9. Spend ultrasound examination of the abdominal cavity in the standard (gray-scale) mode.
10. List the main echographic signs of possible changes in the abdominal cavity in acute pancreatitis.
11. List the main ultrasound markers of pancreatic imaging.
12. List the main features of the evaluation of the gallbladder ultrasound.
13. The main ultrasonic signs of acute myocardial infarction.
14. The major ultrasound signs of acute cholecystitis.
15. The main ultrasonic signs of acute non-destructive pancreatitis.
16. The main ultrasonic signs of choledocholithiasis.
17. The major ultrasound signs of liver steatosis.
18. The main ultrasonic signs of acute hepatitis.
19. Specify the main distinctive features of liver cirrhosis in ultrasound.
20. Give a description of the main features of the echographic picture of the gallbladder in patients with acute calculous cholecystitis.
21. The major ultrasound signs of swelling of the pancreatic head.
22. The basic ultrasonic features of liver metastases.

23. The basic ultrasonic features of liver hemangiomas.
24. The main ultrasonic signs of polycystic kidney disease.
25. The main ultrasonic signs of pelvic dystopia of the kidney.
26. The major ultrasound signs of an abscess of the kidney.
27. The main ultrasonic signs of nephrolithiasis.
28. List the major sonographic signs of changes in the kidney in hydronephrosis.
 29. Describe the basic sonographic symptoms of nephrolithiasis
 30. The main ultrasonic signs of hydronephrosis.
 31. Ratio of the volume of the thyroid gland depending on the gender in adults.
 32. The main ultrasound features of autoimmune thyroiditis.
 33. The main ultrasonic signs of a malignant tumor of the thyroid gland.
 34. The basic ultrasound characteristics of thyroid adenoma.
 35. Formulate the basic rules for the formation of a standard medical report on the results of ultrasound.
 36. Describe Doppler signs in patients with occlusive lesions of the arteries of the lower extremities.
 37. Describe the main echographic signs of atherosclerotic lesions of the carotid artery.
 38. Describe the main echographic signs of thrombophlebitis.
 39. Describe the main echographic signs of phlebothrombosis.